Focused Ultrasound Treatment of Pediatric Benign Brain Tumors

International Virtual Workshop

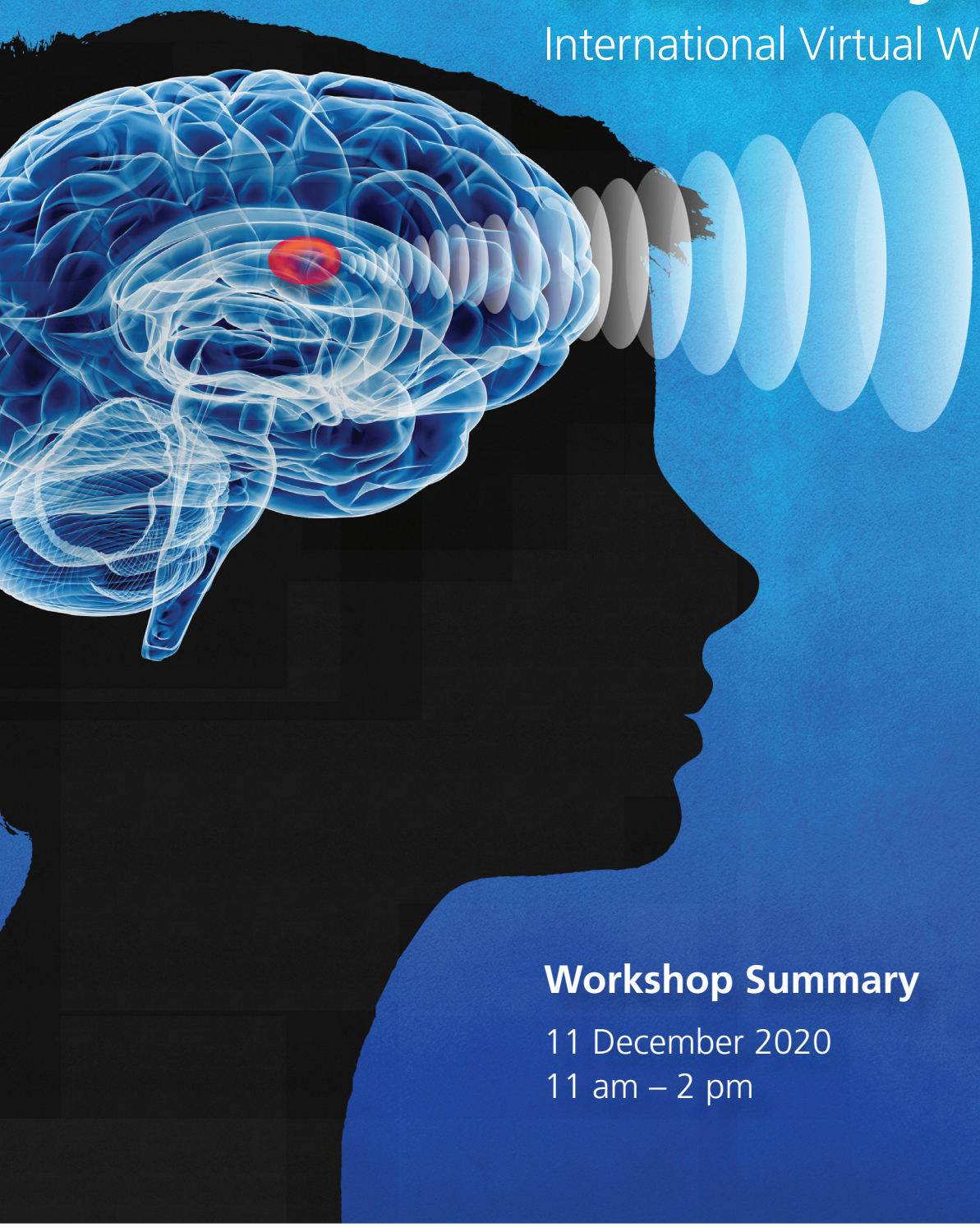

Workshop Summary

11 December 2020
11 am – 2 pm

Sponsored by

Focused Ultrasound Foundation



Contents

Executive Summary

Twenty clinician experts met with industry leaders and representatives from the U.S. Food and Drug administration (FDA) in a workshop organized by Dr. John Ragheb with the assistance of the Focused Ultrasound Foundation. Their goal was to discuss current practices for treating benign pediatric brain tumors, review the **ongoing clinical trial** using focused ultrasound, and determine a roadmap for advancing the use of focused ultrasound to treat these difficult tumors.

Five experts presented on the state of the field. Travis Tierney summarized the ongoing clinical trial at Nicklaus Children's hospital and described some of the treatments in the five patients enrolled to date, including an unsuccessful case that was likely due to calcifications near the target. Mor Dayan from Insightec followed with a more detailed review of the technological challenges of treating benign pediatric brain tumors with focused ultrasound and described Insightec's ongoing efforts to improve the capabilities of the Exablate Neuro transcranial focused ultrasound system. Dan Curry spoke about current surgical treatments for benign pediatric brain tumors, and Roger Packer discussed the best existing medical treatment. Adam Waspe shared some ongoing research projects and future research projects at the Hospital for Sick Children in Toronto.

A lively discussion period engaged all attendees and revealed some common themes:

1. the need to target appropriately sized tumor volumes (5 to 10 cc), appropriate tumor types (World Health Organization [WHO] grade I and II), and tumors with discrete, localized lesions rather than infiltrative tumors;
2. concerns about the volume of resection as a limiting factor;
3. blood–brain barrier (BBB) opening, histotripsy, liquid biopsies, and immunotherapy as possible biomechanisms; and
4. the need to include functional outcome measures in evaluation criteria.

Because the discussion was so rich and informative, there was insufficient time for the group to reach consensus about the next steps to advance the use of focused ultrasound to treat benign pediatric brain tumors. After the white paper is distributed, attendees agreed to continue the discussion via Zoom to reach consensus and inform design of the next research study.

. . . . .

Welcome, Introductions, and General Information

John Ragheb welcomed attendees to and described the workshop as an exciting opportunity for the pediatric focused ultrasound community to discuss the best way to move this technology forward to treat benign brain tumors and epilepsy. The workshop's overarching goal was to develop a useful roadmap based on the attendees' scientific expertise and their vision for the future of pediatric focused ultrasound. The participating groups introduced themselves (see attendee list at the end of this document). The meeting materials included copies of several publications and one submitted manuscript on using focused ultrasound to treat epilepsy.[1–4]

. . . . .

Workshop Presentations

To provide an overview of the topic and set the stage for discussion, the workshop included presentations from several attendees. These clinical and technical talks revealed the current state of the field by describing

1. the current use of focused ultrasound to treat patients and the technical capabilities of the Insightec Exablate Neuro focused ultrasound brain system and
2. the current standard of care for using surgery, medical management, and chemotherapy to treat benign pediatric brain tumors. A review of clinical experience with focused ultrasound for these conditions completed the presentation section of the workshop.

. . . . .

Prior Treatments with Focused Ultrasound

Travis Tierney presented a concept overview and several case examples of the use of transcranial focused ultrasound to treat adults for essential tremor (ET) and children for benign brain tumors. Dr. Tierney began by reviewing basic focused ultrasound transducer concepts and practical principles for thermocoagulation, skull geometry, and the acoustic envelope. He then explained how ET became the first FDA-approved clinical indication for using focused ultrasound as a brain lesioning technique by performing a thalamotomy. For ET, stopping the tremor and improving quality of life were the primary and secondary efficacy goals, respectively. The clinical trial process allowed for fine tuning of the focused ultrasound lesioning procedure and maximized success by including patients with a skull density ratio higher than 0.40, heating to an optimum temperature of 54° C, and targeting the ventral intermediate nucleus of the thalamus with millimeter-specific precision. The approved acoustic envelope for thermal ablation is currently centralized to only the deep brain structures, but recent research has been expanding it to more superficial locations.

Dr. Tierney presented the following rationale for using focused ultrasound in pediatric neuro-oncology applications:

- No dose of ionizing radiation is statistically safe.
- Focused ultrasound can provide incisionless, non-ionizing tumor ablation.
- Focused ultrasound is a safer alternative or adjuvant to
  - conventional surgery/invasive procedures (open, endoscopic, and embolization);
  - laser interstitial thermal therapy (LITT); and
  - conventional radiotherapy, including external beam radiotherapy, stereotactic radiosurgery (SRS), and brachytherapy.

After describing his FDA-approved clinical trial protocol for using focused ultrasound to treat benign, centrally located intracranial tumors in children and young adults, Dr. Tierney presented one successful and one unsuccessful case from the cohort of enrolled participants. The successful case was in a female aged 22 years with a large brain hamartoma presenting with gelastic seizures. The case that revealed the limitations of the technology was in a male aged 19 years with a history of tuberous sclerosis. Attempts to treat his subependymal giant cell astrocytoma (SEGA) tumor were unsuccessful due to cavitation during the sonications; thus, the procedure was terminated.

Dr. Tierney concluded his presentation by providing the following take-home messages:

- Focused ultrasound can be used under general anesthesia to treat subcortical epilepsy associated with hypothalamic hamartoma (HH).
- Focused ultrasound yields a highly conformal, instantaneous lesion, which cannot be achieved with LITT or SRS.
- Focused ultrasound–induced cavitation is a concern but may serve as a tool as the technology advances.
- Focused ultrasound does not use radiation, does not induce hemorrhage, and has no risk for infection. It promises to be a safe technology in many ways.
- The industry is exploring the requirements to achieve regulatory approval for this indication.
- The clinical trial remains open to enrollment for five more participants, and attendees are welcome to refer appropriate patients for consideration.

Technical Capabilities

Exablate Neuro

Mor Dayan described the technical capabilities of the Exablate Neuro magnetic resonance–guided focused ultrasound (MRgFUS) system and the technical challenges when treating benign brain tumors. After discussing the treatment continuum from invasive to noninvasive, Mr. Dayan described how MRgFUS is well situated to become the standard of care with its steerable delivery of acoustic energy, real-time imaging, and thermometry capabilities. MRgFUS is currently available at 650 Khz and 220 Khz. Its three modes of therapy, or mechanisms of action, are ablation, neuromodulation, and BBB disruption. It has the potential to impact as many as 200 million patients. Worldwide, MRgFUS is commercially approved to treat ET, Parkinson's disease, and painful bone metastases. It is under clinical trials to treat epilepsy, glioblastoma multiform (GBM), obsessive-compulsive disorder, depression, benign tumors, opioid addiction, brain metastases, diffuse intrinsic pontine gliomas (DIPGs), Parkinson's dementia, Alzheimer's disease, and amyotrophic lateral sclerosis. The current clinical trial for pediatric brain tumors is enrolling patients with a wide range of WHO grade I tumors; most notably HHs, SEGAs, tuberous nodules, gangliogliomas, and dysembryoplastic neuroepithelial

tumors. (**Dr. Tierney** later added that patients with pilocytic tumors are also eligible.) For pediatric patients, successful MRgFUS lesioning is highly dependent on the skull's acoustic characteristics, such as thickness, surface area, and density. The use of the stereotactic frame, positioning, and head shaving requires expert patient management and communication. Anesthesia may help to mitigate some of these patient management aspects. Furthermore, future treatments may eliminate the need for the frame and head shaving.

MRgFUS currently has a small treatment envelope in the brain, so lesioning becomes a factor for tumor debulking when the entire tumor is not within the envelope that the technology can reach. However, a complete lesion is not always necessary to obtain a positive clinical outcome. Other opportunities might lie within tumor disconnection, treatment of a remnant of a tumor that is located within a treatable area, or use of mechanical tissue destruction, neuromodulation, or BBB disruption rather than ablation. Delivering low energy to abnormal neural networks may be adequate to interrupt and reset the signal, as reported in one case study.[2] BBB disruption prior to radiotherapy has been shown to reduce irradiation toxicity.[5] BBB disruption also has been shown in preclinical studies to induce tumor shrinkage, enhance liquid biopsies, and allow fluorescence agents to guide surgical resection.

Surgical Treatment of Benign Central Brain Tumors in Children

Dan Curry described current surgical treatments for HH, a rare type of pediatric epilepsy that causes gelastic and other types of seizures along with other symptoms, such as encephalopathy, precocious puberty, hypothalamic obesity, or rage attacks. Diagnosis is frequently delayed, and the seizures are notoriously resistant to medical management.[6] HHs are generally not considered a conventional tumor, because they do not grow. The purpose of operating on HHs is to control epilepsy and resume normal childhood development. Surgical intervention can be open, endoscopic, or ablative. The emergence of new, minimally invasive technologies may improve the profoundly complicated risk/benefit ratio presented by HH treatment options. HH classification scores are used to plan the various surgical approaches, and the treatment goals are to cure the epilepsy, palliate the epileptic encephalopathy, reduce the rage attacks, and avoid complications. The surgical goals are to completely destroy the HH or disconnect its neural pathways via a staged approach of small, incremental sessions.

Dr. Curry briefly described each of the following current surgical approaches, along with their challenges:

- Open transcallosal interforniceal resection
- Open orbitozygomatic approach
- Endoscopic resection

- Endoscopic disconnection
- Stereotactic laser ablation (including MRgLITT and laser thermal ablation systems)
- Stereotactic radiosurgery
- Stereotactic radiofrequency lesioning
- Stereotactic interstitial therapy

Surgeons use magnetic resonance imaging (MRI) thermography for guidance during some of these procedures. Beyond surgery, physicians have also considered using deep brain stimulation (DBS) to treat HH seizures.

Dr. Curry has published positive results using MRgLITT to treat HHs.[7] His group reported that ablating approximately 60% of the HH led to excellent results in terms of reducing seizure activity, but complications remain, including post-ablation edema (treated with perioperative steroids), memory deficits, transient diabetes insipidus, hypothalamic obesity, sodium disturbances, and cranial nerve paresis.[8] Ablative treatments can also lead to Korsakoff's syndrome and heat sinks. More research is needed to determine the HH's "hot spot," or principal target area, and novel resting state functional MRI techniques may help determine the best surgical roadmap. Patients with giant hamartomas are special HH cases because they have high preoperative and intraoperative morbidity, as well as other complications such as salt wasting. The optimal disconnection strategy for these cases is unknown but a work in progress.

Focused ultrasound can improve the risk/benefit ratio for patients with HH if it can provide zero co-morbidity and an improved safety profile and be performed as an outpatient procedure, possibly with nonthermal lesioning. The challenges to using focused ultrasound to treat HH may include:

- Dosing in immature crania: the earlier the surgery the better the outcomes.
- Dosing in fluid interfaces: is cavitation an issue or a potential mechanism?
- Accuracy: 1 mm can matter—see ablation complications.
- Lesion size versus ablation volume mismatch: is this like the radiofrequency era?
- Refinement of disconnection strategies, mapping inter-hamartoma connectivity: the Yamaguchi et al. case study is especially interesting because of its use of tractography.[3]
- Inferior energy dispersal around eloquent structures.

In conclusion, MRgLITT has reduced morbidity and increased the efficacy of HH surgery, but more can be done. Focused ultrasound may hold advantages over MRgLITT, but it may require a disconnective approach, in which the entire tumor is not resected and the treatment is applied to the tumor's stalk, or attachment site.

Contemporary Medical Management of Pediatric Gliomas

Roger Packer described the contemporary medical management of pediatric low-grade gliomas, including the use of chemotherapy and molecular-targeted therapy. Dr. Packer began by describing the epidemiology of pediatric low-grade and high-grade gliomas, including the differences between pediatric and adult tumors, in origin, histology, grade, and incidence. Because of these differences, and recent understandings of the molecular drivers of pediatric gliomas, the treatments for pediatric gliomas and for similarly graded tumors in adults differ substantially. In addition, age is a major consideration in the management of pediatric low-grade gliomas, because the field is appropriately reluctant to use radiation early in life when brains undergo critical periods of development. The prognosis for pediatric low-grade gliomas also differs from that for adults, because most pediatric low-grade gliomas remain low-grade during the pediatric years and transform into high-grade gliomas during adulthood less frequently than do adult low-grade tumors.

The reluctance to use radiation therapy in pediatric patients with low-grade tumors and mixed neuronal glial low-grade tumors makes them excellent candidates for focused ultrasound treatment. Pediatric patients with posterior fossa ependymomas, especially those arising close to the brainstem and/or occupying the cerebellopontine angle, may also be good candidates for focused ultrasound. Overall, focused ultrasound should be considered a potential treatment for the majority of the WHO grade I and II central nervous system tumors occurring in children.

Low-grade pediatric gliomas in young children are primarily pilocytic (grade I) astrocytomas, and the majority of pilocytic astrocytomas have aberrant signaling of the RAS mitogen-activated protein kinase (RAS-MAPK) signaling pathway. The most common mutation in sporadic low-grade pilocytic astrocytomas are BRAF fusions. These activating fusions are an excellent target for molecular-targeted therapy. The second most common mutation is a point mutation in the BRAF gene; usually a V600E mutation in which valine (V) is substituted by glutamic acid (E) at amino acid 600. Other fusions and mutations resulting in overactivation of the RAS-MAPK may occur; however, in total they probably constitute less than 10% to 15% of the molecular abnormalities that underlie pediatric low-grade tumors. Neurofibromatosis type 1 (NF1)-associated low-grade gliomas are also driven by aberrant signaling of the RAS-MAPK, because neurofibromin (a negative regulator of RAS) loss, which occurs as a result of NF1 loss, activates the RAS-MAPK pathway. In the majority of pediatric low-grade gliomas, the RAS-MAPK is the only signaling pathway that is significantly activated, making such tumors excellent candidates for molecular-targeted therapy; biologically important signaling through alternative pathways to mediate resistance usually does not occur.

Abnormalities of the RAS-MAPK pathway, including BRAF fusions and V600E mutations, have been seen in many patients with mixed neuronal glial tumors, such as gangliogliomas, also making them excellent potential targets for therapy. The decision on whether to treat a child is often a careful calculation of the probable morbidity of the tumor, such as progressive visual loss in patients with visual pathway gliomas, and the natural history of such lesions, versus the potential toxicities of the therapy chosen.

The current standard of care for sporadic and NF1-associated low-grade gliomas that require treatment is chemotherapy. Although a variety of different regimens have been used, the most frequent has been the combination of carboplatin and vincristine. More than 1,400 children have been treated in prospective clinical trials over the past 10 to 20 years with the carboplatin and vincristine regimen. For those with NF1, treatment is successful in halting disease in greater than 90% of the cases, and approximately 66% to 75% of those treated will never require another form of treatment. Treatment is nearly as effective for initial control of tumor in patients with non-NF1 low-grade gliomas. However, approximately 70% of children with sporadic tumor will require either retreatment or an additional form of treatment within three years of completing therapy. In addition, chemotherapy has both short-term and long-term toxicities and, even when effective, infrequently results in marked clinical improvement.

Molecular-targeted therapy is a newer form of treatment that is increasingly being used. Bevacizumab (an anti-angiogenesis agent) and irinotecan, as well as bevacizumab alone, have been effective for treating some tumors that have failed radiation and chemotherapy. This type of rescue medication has demonstrated dramatic functional benefits. Unfortunately, in most patients, treatment is only effective while the child is receiving the treatment, and tumors quickly recur after treatment has stopped.

Other, more specific molecular-targeted therapies have shown great promise in both the treatment of low-grade gliomas harboring both BRAF fusions and mutations and the treatment of NF1-associated low-grade gliomas. The use of selective MEK inhibitors to block the signaling of the aberrant RAS-MAPK pathway has changed the paradigm of the treatment of these diseases and, like bevacizumab and irinotecan, may result in clinical response. As many as 75% of sporadic low-grade gliomas respond to MEK inhibitors with tumor shrinkage—or at least stabilization of disease. In one series of children with sporadic low-grade gliomas who had an underlying BRAF fusion abnormality, a greater than 50% shrinkage was seen in 40% of patients. In the same study in children with NF1-associated low-grade gliomas, some degree of shrinkage was seen in almost every child. Randomized clinical trials with several different MEK inhibitors are currently under way. Children with BRAF V600E mutations have also been successfully treated with MEK inhibitors, but there is increasing experience that BRAF inhibitors, are also as, if not more, effective, in this subgroup of patients.

Focused ultrasound may be extremely useful in patients who ultimately relapse despite receiving molecular-targeted therapy. There are now randomized clinical trials in children with newly diagnosed disease comparing chemotherapy to molecular-targeted therapy for those with NF1-associated low-grade gliomas, low-grade gliomas harboring a BRAF V600E mutations, and sporadic low-grade gliomas demonstrating BRAF fusions.

The following types of tumors may be amenable to high- or low-intensity focused ultrasound treatment, including BBB opening:

- Juvenile polycystic astrocytomas, especially those that are in critical or eloquent areas of the brain
- Isolated optic nerve tumors

- Diffuse infiltrating tumors in children with and without NF1 that have one focal area that seems to be growing
- Neuronal and glioneuronal mixed tumors (see WHO classification 5th edition), especially those that are deep seated and/or causing intractable seizures
- Pediatric gliomas with known molecular signatures that are not presently well treated with currently available molecular-targeted therapy

The challenges for treating pediatric gliomas are significant, including balancing the efficacy of whatever agent or approach is used and its ability to target the leading-edge of infiltrating tumors against the long-term potential toxicities of treatment. Outcome cannot be measured by progression-free survival or response alone: Determination of neurologic function, visual function, and quality-of-life after treatment are critical to understanding of the effectiveness of treatment and how treatment should be prioritized for children with low-grade gliomas and mixed neuronal glial tumors.

. . . . .

Focused Ultrasound Research Site Reports

John Ragheb invited attendees to describe their experience either studying or using transcranial focused ultrasound to treat pediatric brain tumors and other related conditions. These reports are summarized below.

SickKids, The Hospital for Sick Children

James Drake said that SickKids conducts a wide variety of preclinical studies that apply to focused ultrasound brain applications, even though it does not have a clinical brain system. **Adam Waspe** described several brain and non-brain projects, which involve multiple regional collaborations:

- Computer simulation of wave propagation and heat transfer for bone and soft tissue high-intensity focused ultrasound (HIFU) treatment
- Acoustic radiation force imaging (ARFI) and motion compensation for MRI thermometry
- MRI-compatible robotics for HIFU positioning
- Hyperthermia-induced drug delivery for solid tumors
- Noninvasive treatment of fetal/placental vascular malformations using MRgHIFU
- Clinical treatment of benign bone and soft tissue tumors using MRgHIFU ablation
- Treatment of pediatric neurological disorders using transcranial MRgHIFU

Researchers at SickKids are also studying ultrasound transmission, characterization, and acoustical refocusing across the pediatric skull (measurement, modeling, and ARFI); sonothrombolysis of blood clots from intraventricular hemorrhage of prematurity;

diffusion tractography to guide thermal ablation of white matter tracts in epilepsy; and BBB disruption for liquid biopsy–based brain tumor diagnosis.

While characterizing pediatric skulls, the SickKids team has determined that the composition and properties of the pediatric skull vary greatly with development in terms of thickness, number of layers, and the presence of fontanelle or sutures. There is minimal loss of energy, minimal acoustic wave distortion, and low time-of-flight delay when applying focused ultrasound through a neonate skull. An 8-year-old skull behaves similarly to that of older children, so a phased array and stereotactic frame would be needed to treat younger patients.

Dr. Waspe and his team are using short bursts of focused ultrasound with a low duty cycle in an in vitro setting to create long-pulse (boiling) histotripsy with minimal thermal effects to mechanically liquify blood clots. This technique may be an effective use of sonothrombolysis for intraventricular hemorrhage (IVH) of prematurity. The range of sonication parameters for complete clot lysis are as follows:

- Acoustic Power = 400 to 800 watts
- Pulse Duration = 1 to 10 milliseconds
- Pulse Repetition = 0.2 to 1 hertz
- Duty cycle = 1%

The team is also developing a porcine model of IVH using neonatal piglets. After inducing thrombolysis with MRgHIFU, they tested the model over the past year and found promising results for decreasing ventricular volume with the histotripsy technique.

Robotic HIFU transducer positioning is another area that SickKids is developing for the Profound Medical Sonalleve focused ultrasound system. Accuracy testing of the robot in thermally sensitive phantoms has occurred during the past several months.

Researchers are also using HIFU to ablate white matter tracts through a cranial window in a young healthy porcine model. The team has been able to capture high-resolution diffusion tensor imaging scans before and after treatment of the fornix to visualize substantial tract disruption in the lesion area. The damage is most severe in the lesion core and decreases radially.

For liquid biopsy, the team is measuring cerebrospinal fluid (CSF) biomarkers from DIPGs, because DIPGs located near the brain stem are difficult to biopsy. Because the BBB prevents the biomarkers from reaching the bloodstream, these researchers are using focused ultrasound and microbubbles to disrupt the BBB and capture the DIPG tumor–derived biomarkers from the CSF as they travel into the bloodstream, and then fluorescently tag them. These specialized, liposome-enhanced microbubbles are being engineered in the Matsuura Laboratory at the University of Toronto.

George Ibrahim briefly described his interest in mapping brain lesions using advanced lesion network mapping tools.

Boston Children's Hospital

Joseph Madsen stated that Boston Children's Hospital has followed the focused ultrasound work at Brigham and Women's hospital for quite some time. Determining the most highly relevant pediatric indications that could compliment Boston Children's surgical practice is of interest, including in the areas of sonothrombolysis and epilepsy treatment. This group is also interested in non-ionizing treatment approaches. **Scellig Stone** echoed his interest in clot lysis and said that any liquid biopsy techniques would be useful.

. . . . .

Stanford University Medical Center

Stanford participated in clinical trials for ET and Parkinson's dyskinesia and recently opened a study of temporal lobe epilepsy. The first patient was treated in November 2020. **Pejman Ghanouni** added that Stanford researchers are also working with Insightec and others to develop autofocusing with microbubbles to expand the brain treatment envelope.

. . . . .

Carlos Besta Neurological Institute

The Carlos Besta team currently uses focused ultrasound to treat adult patients with movement disorders. **Francesco Prada** conducted research on pediatric brain tumors during his fellowship at the Focused Ultrasound Foundation and is interested in either supporting the efforts of others or initiating a pediatric program at Carlos Besta. He noted that sonodynamic therapy and BBB disruption for DIPG are indications currently in development that could be used to treat children. The Carlos Besta team is planning a low-intensity focused ultrasound 5-aminolevulinic acid sonodynamic therapy study in adults with glioblastoma. It is also building an atlas of microbubble distribution in the brain to aid in treatment planning.

. . . . .

Next Steps

Attendees brainstormed ideas for designing a clinical trial protocol to treat benign pediatric brain tumors. They discussed the types of lesions that might be treatable with focused ultrasound; treatment planning, patient selection, targeting, and treatment time; other biomechanisms of focused ultrasound; and FDA approval.

Brain Lesions That Might be Treatable with Focused Ultrasound

The entire group discussed the pathologies and size, or volume, of various brain lesions that might be treatable within the current technological capabilities of transcranial focused ultrasound. The group raised the following ideas:

- Select WHO grade I or II brain tumors could be considered for treatment with focused ultrasound.
- Localized lesions, such as ependymal tumors, are likely better candidates than infiltrating lesions such as widely infiltrating pilocytic astrocytomas.
- Epilepsy is an indication that could likely benefit from the technology. HH volume ablation could be a starting point. Lesioning is not the solution for all epilepsy cases, but identifying a functional outcome is important for each case.
- Focused ultrasound could create hemorrhages from vascular lesions.
- Congenital brain malformations, small cortical dysplasias, or lesions in the deep part of the frontal cortex are possible treatment targets for focused ultrasound. With the exception of cortical lesions, these lesions and subependymal hamartomas would be a good match for the treatment volume that focused ultrasound can provide. The treatment of cortical lesions remains in preclinical stages, but hopefully nonablative techniques can be used to reach these areas.
- If its safety over current treatment alternatives could be proven, focused ultrasound could be used for the repetitive treatment of slowly growing tumors that need recurrent treatment without radiation, surgery, or other damaging modalities. The treatment of HHs could be used as an example.
- It would be helpful to determine what could be learned from adult focused ultrasound studies and from other ablative therapies, such as LITT.

Treatment Planning, Patient Selection, Targeting, and Treatment Time

An attendee reminded the group that pediatric diseases require a long-term view, not a one-time treatment approach, and added that iterative strategies work well across a broad spectrum of diseases and pathologies.

Besides thermometry, intensity modeling is a useful tool for treatment planning of thermal dose or any other clinical result. Modeling can provide feedback on intensity thresholds, be simulated in advance, and can be used in real time during the treatment process. Stanford University is a leading center for measuring ARFI and acoustic energy deposition. Sunnybrook Research Centre also conducts important research in this area for spatial monitoring.

Selecting patients that would potentially benefit from the procedure and then building functional outcome measures (e.g., epilepsy, vision, motor function) should be considered when designing a clinical trial. Progression-free survival is not an adequate outcome measure, especially for low-grade gliomas. An ideal study would measure both progression-free survival and functional outcomes in an expanded cohort.

Insightec's treatment approach is based on targeting accuracy within a few millimeters. After the exact target is confirmed, the temperature is set to provide a transient effect prior to creating a permanent lesion at a higher temperature. Pediatric treatments also begin with a conservative approach to targeting and lesion location. More experience with benign tumors will expand the system's capabilities and the types and sizes of the tumors treated. A new treatment technique, currently in clinical trials, is also expected to decrease treatment times.

The anterior thalamic nucleus would be a good, small, and forgiving target for focused ultrasound treatment of epilepsy. Use of deep brain stimulation to treat this target has several downsides, and the hardware does not last as long in children as it does in adults. A current adult clinical trial at The Ohio State University is targeting the thalamic nucleus for patients with epilepsy. The lead investigator is Vibhor Krishna, and two patients have been treated.

A clinician's first procedure to treat a brain lesion with focused ultrasound usually can be prolonged. For example, one attendee said that his first thalamotomy spanned 6 hours and his first HH spanned most of the day. This learning curve also exists for other new technologies, and focused ultrasound is still in the early stages.

. . . . .

Other Biomechanisms of Focused Ultrasound

Beyond ablation, attendees discussed the potential use of other biomechanisms of focused ultrasound to treat benign pediatric brain tumors. Because focused ultrasound–induced BBB opening is being studied for the treatment of Alzheimer's disease, dementia, neuropathic pain, GBM, and more, the group discussed alternative biomechanisms for treating brain lesions—including histotripsy, BBB opening, liquid biopsy, and immunotherapy. The following ideas emerged from the discussion:

- Various mechanisms of focused ultrasound can be used for blood clot liquification.
- Histotripsy, the inertial cavitation approach in use by the University of Michigan, shows promise for leveraging the mechanical effects of focused ultrasound to treat the brain.
- Gene therapy and liquid biopsy might benefit from the use of focused ultrasound for BBB opening.
- The use of focused ultrasound to improve the process of sampling CSF and blood for liquid biopsies of tumor biomarkers would have a substantial impact on
  - differentiating between BRAF fusion proteins and BRAF point mutation tumors, because a fusion can be exacerbated by treatment with a point mutation drug; and
  - obtaining liquid biopsy data, which could provide incredibly valuable diagnostic follow-up information and eliminate the need for tumor biopsies.
- Developing liquid biopsy capabilities would be a game changer because no method to do so currently exists.
- Collecting neuro-immunological data, such as antigen presentation and tumor infiltration after focused ultrasound, should also be considered when planning clinical trials.
- Low-intensity focused ultrasound holds potential for expanding indications over the long term—especially for liquid biopsy and drug delivery.

FDA Approval

Obtaining FDA approval for conducting pediatric studies is an important part of clinical trial design. Attendees discussed the following points:

- Sponsors and PIs should talk to the FDA before beginning to plan any study, because the FDA will specify what researchers must prove during the study. Insightec has not yet begun the process of working with the FDA to design a new pediatric protocol.
- Achieving FDA approval for one isolated indication is different from what is typically seen in pediatrics.
- LITT achieved FDA approval for treating the entire brain. The reason that it received a broad approval was that it was submitted as a tool for cutting, not a tool for treating a specific condition. It is a stereotactic and precise tool for cutting, and it is up to the surgeon to decide what to cut.
- Attendees cautioned that it may not be advisable to duplicate existing treatment options, such as LITT.
- The Profound Medical Sonalleve device was recently approved for the treatment of pediatric osteoid osteoma under the humanitarian device exemption (HDE). This regulatory pathway might be useful for additional rare disease indications. The open clinical trial enrolled nine participants at one treatment site. DBS treatment was also approved under the HDE pathway, setting precedence for brain indications.
- Imaging will be an important part of any treatment or neuromodulation study.
- A cultural shift toward accepting a new technology like focused ultrasound will be needed.

Future Project Funding Assistance

The Focused Ultrasound Foundation creates funding opportunities and partners with other organizations to fund preclinical, translational, and clinical research. It welcomes suggestions for local and regional funding partners.

. . . . .

Conclusion

John Ragheb encouraged attendees to send additional ideas to him and the Focused Ultrasound Foundation. **Tim Meakem** thanked attendees for their valuable contributions to the workshop and added that the Foundation will continue to organize discussions around this topic so that consensus can be reached for the next study.

. . . . .

FDA Commentary

After the conclusion of the workshop, representatives from the FDA sent a document outlining their recommendations, as follows:

1. We cannot speak for the regulatory scientists and clinicians, but from the perspective of ultrasound scientists, we think that the difficulties associated with thermal ablation procedures in the pediatric brain will make regulatory approval in the near future a challenge. For reasons talked about in the symposium (including sonicating at steep angles), demonstrating a targeting ability to within about 1 mm accuracy (depending upon the location) will be difficult. The targeting-accuracy requirements for BBB opening are less stringent, and the intensities are much lower than ablation. BBB procedures may be a better avenue to pursue once efficacy in adults has been confirmed.

2. We do not believe the approach of submitting focused ultrasound as an all-purpose tool in the brain will be fruitful, even though the laser was approved as a cutting tool anywhere in the brain. We do not know the circumstances under which the laser was approved. Knowing the effects that ultrasound can have on nerves and blood vessels, we think that the impact of the ultrasound energy is very location specific, and that should be addressed in the submission. The submission should contain a thorough risk analysis for the particular application. In other words, we think context of use will be important.

3. It was suggested that the HDE be considered as a possible approval mechanism for pediatric applications, given the small number of subjects required for clinical

evidence. We think if there is truly a humanitarian emergency, the HDE should be pursued. However, if commercialization of focused ultrasound for pediatric applications is the goal, the HDE is not appropriate. It should be kept in mind that commercialization is not allowed under an HDE (only recuperating study costs). If the standard paths to commercialization appear burdensome, let's work together to reduce the burden.

4 Off-label use was mentioned in the symposium. A concern about off-label use is that a thorough discussion of the risk associated with the desired use might not have occurred. If that happens, the likelihood of an adverse event increases. An avoidable adverse event associated with a focused ultrasound procedure can significantly delay acceptance of the technology.

5 We encourage those interested in obtaining FDA approval for a focused-ultrasound device or procedure to go through the Q-submission (**https://www.fda.gov/media/93740/download**) process. The procedure has no fee, and FDA will assemble the complete team necessary to evaluate your information. The team can then advise you of the next steps.

. . . . .

References

1 Ahmed H, Field W, Hayes MT, et al. Evolution of movement disorders surgery leading to contemporary focused ultrasound therapy for tremor. *Magn Reson Imaging Clin N Am.* 2015;23(4):515-522. doi:10.1016/j.mric.2015.05.008

2 Abe K, Yamaguchi T, Hori H, et al. Magnetic resonance-guided focused ultrasound for mesial temporal lobe epilepsy: a case report. *BMC Neurol.* 2020;20(1):160. doi:10.1186/s12883-020-01744-x

3 Yamaguchi T, Hori T, Hori H, et al. Magnetic resonance-guided focused ultrasound ablation of hypothalamic hamartoma as a disconnection surgery: a case report. *Acta Neurochir (Wien).* 2020;162(10):2513-2517. doi:10.1007/s00701-020-04468-6

4 Franzini A, Moosa S, Prada F, Elias WJ. Ultrasound ablation in neurosurgery: current clinical applications and future perspectives. *Neurosurgery.* 2020;87(1):1-10. doi:10.1093/neuros/nyz407

5 Czarnota GJ, Karshafian R, Burns PN, et al. Tumor radiation response enhancement by acoustical stimulation of the vasculature. P*roc Natl Acad Sci.* 2012;109(30):E2033-E2041. doi:10.1073/pnas.1200053109

6 Wilfong AA, Curry DJ. Hypothalamic hamartomas: optimal approach to clinical evaluation and diagnosis. *Epilepsia.* 2013;54 Suppl 9:109-114. doi:10.1111/epi.12454

7 Curry DJ, Raskin J, Ali I, Wilfong AA. MR-guided laser ablation for the treatment of hypothalamic hamartomas. *Epilepsy Res.* 2018;142:131-134. doi:10.1016/j.eplepsyres.2018.03.013

8 Gadgil N, Lam S, Pan I-W, et al. Staged magnetic resonance-guided laser interstitial thermal therapy for hypothalamic hamartoma: analysis of ablation volumes and morphological considerations. *Neurosurgery.* 2020;86(6):808-816. doi:10.1093/neuros/nyz378

Abbreviations

ARFI	acoustic radiation force imaging
BBB	blood–brain barrier
BRAF	human gene that encodes a protein called B-Raf
CSF	cerebrospinal fluid
DBS	deep brain stimulation
DIPG	diffuse intrinsic pontine glioma
ET	essential tremor
FDA	Food and Drug Administration
GBM	glioblastoma multiform
HDE	humanitarian device exemption
HH	hypothalamic hamartoma
HIFU	high-intensity focused ultrasound
IVH	intraventricular hemorrhage
LITT	laser interstitial thermal therapy
MEK	enzymes involved in the mitogen-activated protein kinase signally pathway
MRgFUS	magnetic resonance–guided focused ultrasound
MRgHIFU	magnetic resonance–guided high-intensity focused ultrasound
MRgLITT	magnetic resonance–guided laser interstitial thermal therapy
MRI	magnetic resonance imaging
NF1	neurofibromatosis type 1
RAS-MAPK	RAS mitogen-activated protein kinase, a signal transduction pathway in cell biology
SEGA	subependymal giant cell astrocytoma
SRS	stereotactic radiosurgery
WHO	World Health Organization

Workshop Attendees

Boston Children's Hospital

Joseph Madsen, MD
Pediatric Neurosurgeon

Scellig Stone, MD, PhD, FRCSC
Pediatric Neurosurgeon

Carlos Besta Neurological Institute

Silvia Esposito, MD, PhD
Pediatric Neurologist

Francesco Prada, MD
Neurosurgeon

Children's National Hospital

Robert Keating, MD
Pediatric Neurosurgeon

Chima Oluigbo, MD
Pediatric Neurosurgeon

Roger J. Packer, MD
Pediatric Neurologist

Insightec

Mor Dayan
Senior Director, Product Management of Neuro

Emily Mason, PhD
Clinical R&D Specialist for Neurosurgery

Focused Ultrasound Foundation

John Burns
Systems Administrator

Mark Carol, MD
Neurosurgeon and Brain Program Director

Suzanne LeBlang, MD
Neuroradiologist and Director of Clinical Relationships

Tim Meakem, MD
Anesthesiologist and Chief Medical Officer

Lauren Powlovich, MD
Associate Chief Medical Officer

Paige Rice
Executive Coordinator

Jill W. Roberts, MS
Scientific Medical Writer

Nicklaus Children's Hospital

Marytery Fajardo, MD
Pediatric Neurologist, Neurophysiologist, Epileptologist

John Ragheb, MD
Pediatric Neurosurgeon

Shelly Wang, MD
Pediatric Neurosurgeon

SickKids, The Hospital for Sick Children

James M. Drake BSE, MBBCh, MSc
Pediatric Neurosurgeon

George Ibrahim, MD, PhD
Pediatric Neurosurgeon

Adam Waspe, PhD
Biomedical Engineer, Senior HIFU Project Manager

St. Mary's Hospital & Imperial College London

Travis Tierney, MD, PhD
Pediatric Neurosurgeon

Stanford University School of Medicine

William Brian Gallentine, DO
Pediatric Neurologist, Clinical Neurophysiologist, Epileptologist

Pejman Ghanouni, MD, PhD
Diagnostic Radiologist

Gerald Grant, MD
Pediatric Neurosurgeon

Texas Children's Hospital/ Baylor College of Medicine

Daniel J. Curry, MD
Pediatric Neurosurgeon

James Riviello, MD
Pediatric Neurologist, Epileptologist

Howard L. Weiner, MD, FACS, FAAP, FAANS
Pediatric Neurosurgeon

U.S. Food and Drug Administration

Greg Clement, PhD
Research Physicist

Subha Maruvada, PhD
Therapeutic Ultrasound Program Lead, Acoustics Research Engineer

Matt Myers, PhD
Research Physicist

1230 Cedars Court, Suite 206
Charlottesville, VA 22903

fusfoundation.org